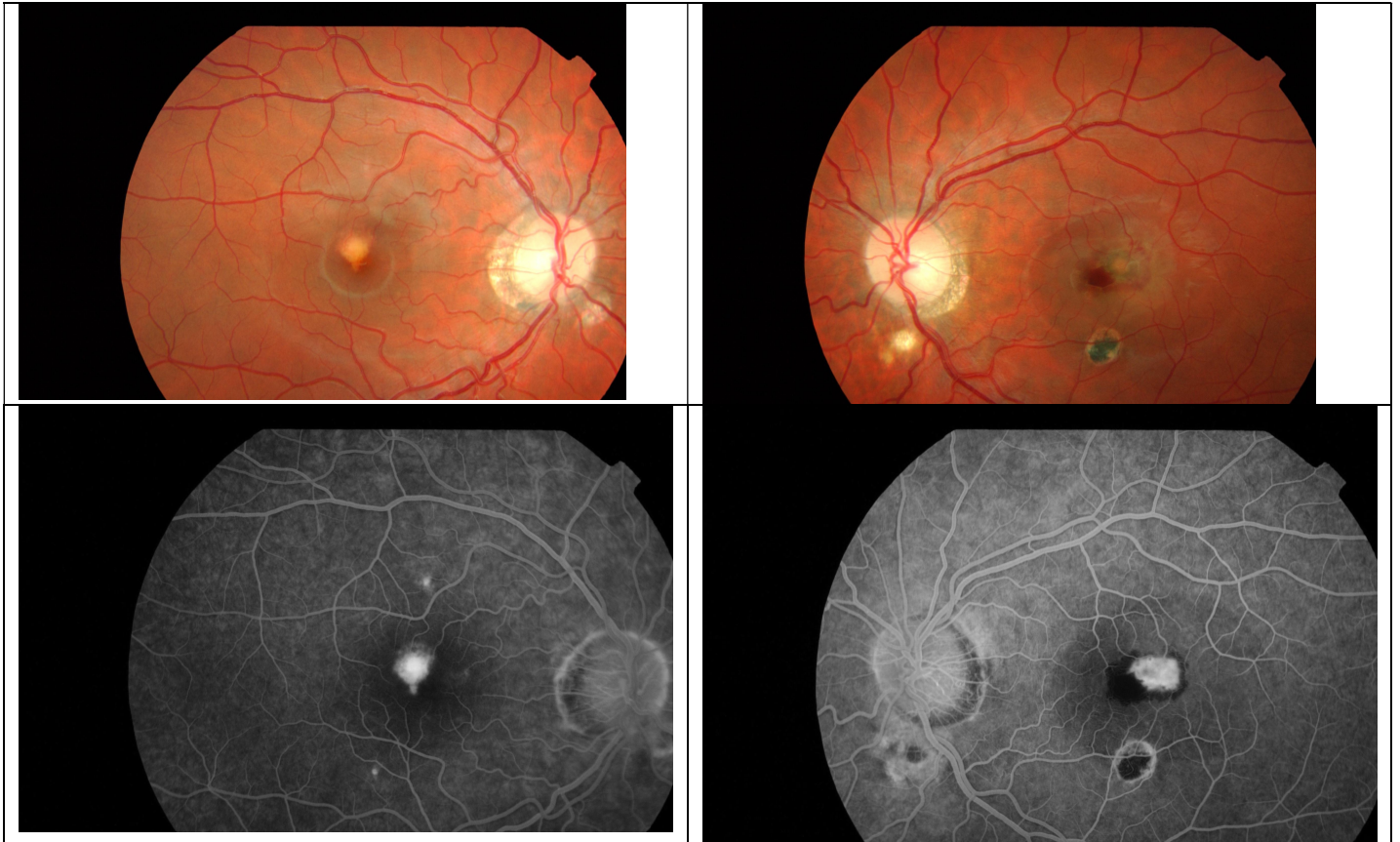


Presumed Ocular Histoplasmosis

Is a clinical syndrome largely found in the Eastern half of the USA of Serous, and haemorrhagic detachment of the macular with peripheral and multiple atrophic chorioretinal scars. There are typically scars scattered around the peripheral fundus.

Usually occurs in healthy people 20 – 50 yrs old.

The loss of central vision is associated with subretinal neovascular membranes.



Treatment of the subretinal neovascular membrane is with Anti-VEGF and is still under evaluation.